

## Autoimmune/inflammatory syndrome induced by adjuvants (ASIA) due to silicone implant incompatibility syndrome in three sisters

R.M. Kappel<sup>1</sup>  
J.W. Cohen Tervaert<sup>2,3</sup>  
G.J.M. Pruijn<sup>4</sup>

<sup>1</sup>Institute for Plastic and Reconstructive Surgery, Zwolle, The Netherlands;

<sup>2</sup>Maastricht University, Maastricht, The Netherlands;

<sup>3</sup>Sint Franciscus Gasthuis, Rotterdam, The Netherlands;

<sup>4</sup>Department of Biomolecular Chemistry 271, Nijmegen Center for Molecular Life Sciences and Institute for Molecules and Materials, Radboud University, Nijmegen, The Netherlands.

Rita M. Kappel, MD, PhD

Jan Willem Cohen Tervaert, MD, PhD  
Ger J.M. Pruijn, PhD

Please address correspondence to:

Jan Willem Cohen Tervaert, MD, PhD,  
Maastricht University, PO Box 5800,  
6202AZ Maastricht, the Netherlands.

E-mail:

[jw.cohentervaert@maastrichtuniversity.nl](mailto:jw.cohentervaert@maastrichtuniversity.nl)

Received on October 9, 2013; accepted in revised form on November 26, 2013.

© Copyright CLINICAL AND

EXPERIMENTAL RHEUMATOLOGY 2014.

**Key words:** ASIA, silicone, monobloc hydrogel, breast implant, genetics

### Competing interests:

R. Kappel is a plastic surgeon at and owner of the Dr Kappel Institute for Plastic & Reconstructive Surgery. The other co-authors have declared no competing interests.

### ABSTRACT

Three sisters who carried the BRCA-1 gene mutation had a preventive mastectomy and were reconstructed with silicone breast implants. After the reconstruction all three patients developed fatigue, arthralgia, myalgia and sleep disturbances within a period of four years. Because the complaints were thought to be related to the silicone breast implants, they were advised to have the implants replaced by non-silicone gel containing Monobloc Hydrogel breast implants. After this replacement operation, all complaints improved as evaluated 2.5 years later. Since the complaints developed during the presence of silicone implants and since the reversal was observed after replacement by hydrogel implants we postulate that our patients suffered from ASIA due to silicone implants, i.e. Silicone Implant Incompatibility Syndrome (SIIS). The generation of this syndrome in three sisters suggests that the susceptibility to the development of SIIS may be genetically determined.

### Introduction

Some patients with silicone breast implants may develop symptoms that are suggestive of an inflammatory or autoimmune diseases (1, 2). When the implants are removed and replaced by the Monobloc Hydrogel implant, which is filled with 97% saline and 3% cellulose, these symptoms either disappear or diminish, which suggests that there is a connection between the silicone implants and the complaints (3). Since not all patients with silicone breast implants develop complaints, we postulate that a genetic predisposition increases the risk to develop Silicone Implant Incompatibility Syndrome (SIIS). Here, we describe three sisters who all experienced complaints after implantation of silicone breast prostheses, providing support for a genetic factor in the development of SIIS.

### Materials and methods

E.F. received her silicone breast implants in 2004 (Mc Ghan style 110, 210 cc); M.F. received her silicone breast implants in 2005 (Mc Ghan style 110,

150 cc); V.F. received her silicone breast implant in 2006 (Mc Ghan style 110, 390 cc). All these intact implants were replaced by Monobloc Hydrogel implants in 2009. Mean age of the sisters at the time of replacement was 50 years.

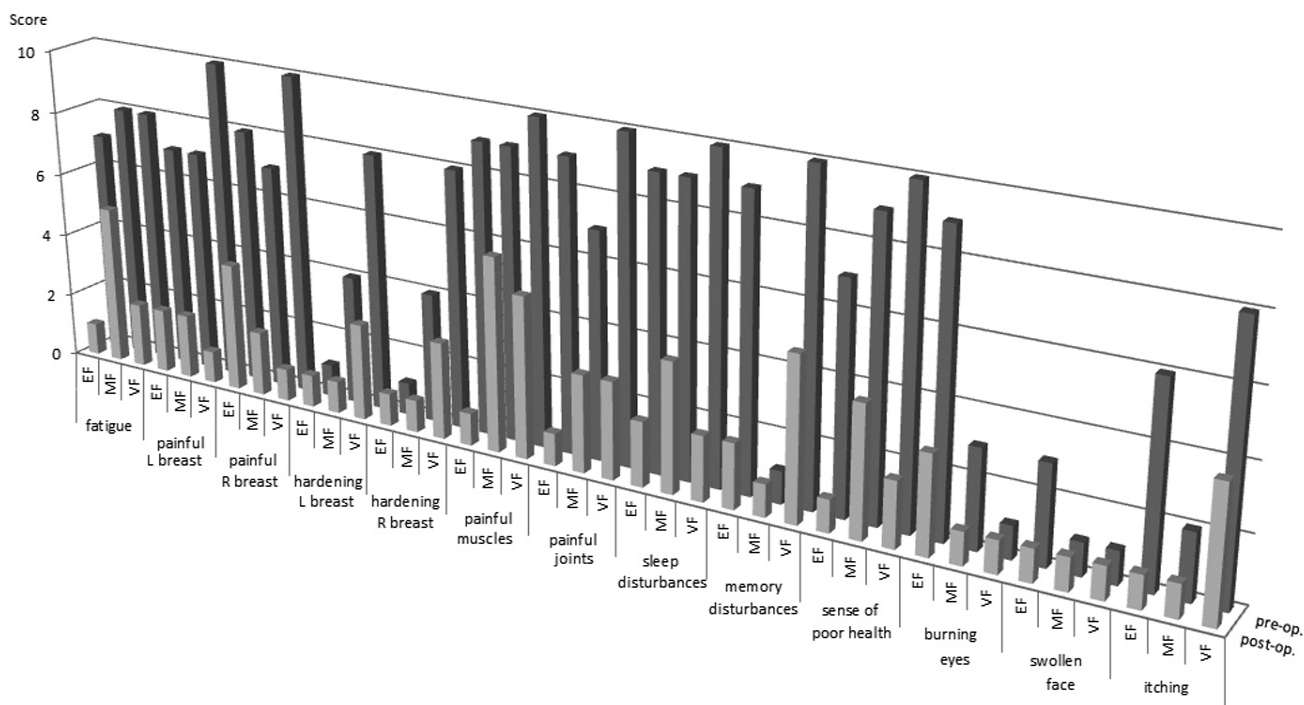
All three patients filled out a questionnaire to evaluate possible complaints that could be related to silicone breast implants (3) before and approximately 2.5 years after implant replacement.

Serum samples taken shortly before and 2.5 years after the replacement were obtained to measure C-reactive protein (CRP), neopterin, immunoglobulin G levels, IgG subclasses and to determine the presence of anti-nuclear antibodies. High sensitivity CRP was determined on a clinical autoanalyser (LX20-Pro, Beckmann Coulter, Mijdrecht, The Netherlands). In healthy subjects, normal CRP levels are <2 mg/l (14). Serum concentration of neopterin was measured by a commercially available enzyme-linked immunosorbent assay (ELISA) kit (IBL, Hamburg, Germany) according to the manufacturer's instructions (15). The presence of anti-nuclear antibodies (ANA) was tested by an indirect immunofluorescence test using HEp-2 cells, whereas immunoglobulin levels (IgG and IgG subclasses) were tested as described (1).

### Results

Three sisters who carried breast cancer-associated BRCA-1 gene alleles were offered a preventive mastectomy. All three had their breasts reconstructed with round, textured, silicone implants. Unfortunately, they all developed subsequently health complaints, which were considered to be related to the presence of silicone breast implants. Silicone gel filled implants were removed and replaced by Monobloc Hydrogel implants, prostheses with a silicone elastomere shell, but filled with 97% saline and 3% cellulose and not with silicone gel. The operations were performed approximately 4 years after the original reconstructions.

To evaluate the effect of the replacement on the health complaints, all three patients completed questionnaires about 2.5 years after the replacements.

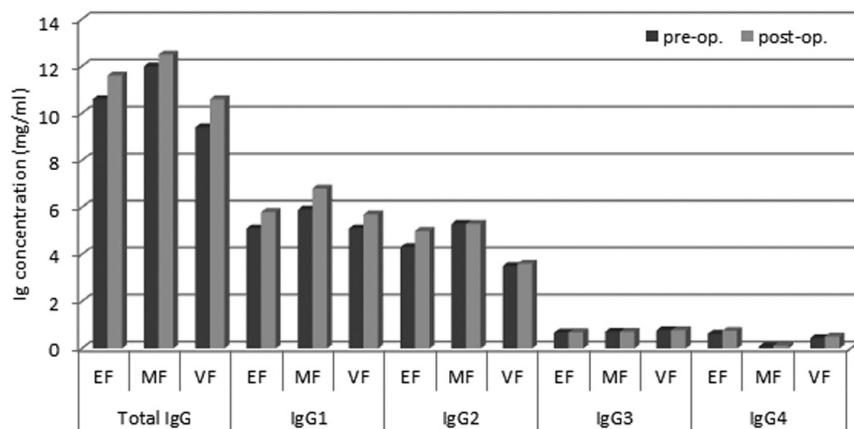


**Fig. 1.** Complaints reported by patients. The questionnaire scores of complaints (specified below the graphs) reported by the three sisters (EF, MF, VF) immediately before (pre-op.; dark grey bars) and 2.5 years after (post-op.; light grey bars) replacement of the silicone implants by Monobloc Hydrogel implants is depicted in the graphs.

**Table I.** Laboratory results before and after removal of silicone implants.

Patient	Sample	CRP (ng/ml)	Neopterin (nmol/l)	Total IgG (mg/ml)	IgG1 (mg/ml)	IgG2 (mg/ml)	IgG3 (mg/ml)	IgG4 (mg/ml)
EF	05/2009	2.5	1.5	10.6	5.05	4.33	0.67	0.62
	01/2012	1.3	1.5	11.6	5.78	4.97	0.69	0.75
MF	05/2009	< 1.0	1.5	12.0	5.90	5.28	0.71	0.09
	01/2012	< 1.0	1.3	12.5	6.80	5.28	0.71	0.12
VF	05/2009	<1.0	1.3	9.4	5.12	3.49	0.77	0.44
	01/2012	1.5	1.1	10.6	5.72	3.57	0.77	0.51

A comparison of pre- and postoperative complaints demonstrated that all three sisters considered their complaints reduced and that overall health improved (Fig. 1). This was not only true for arthralgias and myalgias, but also for several other complaints. Furthermore, all three sisters were satisfied with the aesthetic results after the switch from silicone breast implants to the Monobloc Hydrogel implants. Both before and 2.5 years after the implant replacement serum levels of C-reactive protein (CRP) and neopterin were measured. The results (Table I) did not show significant differences in the levels of these markers, which were in the normal ranges. In addition, immunoglobulin (Ig) G and IgG subclass levels were measured and it was found that IgG levels increased non-significantly post-replacement in all three sisters (Fig. 2), in particular for IgG1. Finally, the presence of anti-nuclear antibodies was assessed. A fine-speckled nuclear staining pattern was observed in all three patients.



**Fig. 2.** Immunoglobulin G levels in patient sera.

The levels of total immunoglobulin G and immunoglobulin G subtypes were determined in the sera of the three sisters (EF, MF, VF) taken immediately before (pre-op.; dark grey bars) and 2.5 years after (post-op.; light grey bars) replacement of the silicone implants by the Monobloc Hydrogel implants.

The percentage of patients who will develop symptoms after silicone breast implants is unknown. We attributed

this complex of complaints, which are possibly related to silicone implants, to “silicone implant incompatibility syndrome (SIIS)” (1).

### Discussion

The observation of SIIS in three siblings strongly suggests that genetic factors may be involved in the development of this syndrome. This may at least in part explain why SIIS is observed in only a proportion of patients with silicone implants, *i.e.* those patients that are genetically predisposed to SIIS development. Importantly, several patients with SIIS have been successfully treated by either only removal of their silicone implants (4) or replacement by the Monobloc Hydrogel implants (3).

We postulate that postponed recognition of a possible relationship between silicone implants and health complaints may diminish the chance for improvement after removing the silicone implants. Subsequently, the condition will worsen and becomes irreversible, resulting in no or little improvement when the implants are removed later. Therefore, it is important to search for relevant predictive factors. Although this case report does not elucidate the molecular mechanism of SIIS development, our data provide the first indications for a genetic predisposition. Several observations suggest that the genetic factor(s) may be related to the immune system: (i) the immunoglobulin G levels in serum might be reduced when silicone implants are present (1,

5); (ii) autoantibodies are present in patients with silicone implants (1, 2, 6); (iii) a number of symptoms are suggestive for autoimmune diseases (1, 2); (iv) several of the autoimmune diseases that are related to SIIS (1) are associated with genetic factors involving genes of the immune system (7).

SIIS may be part of the group of illnesses constituting the ASIA syndrome (Shoenfeld's syndrome) (1, 8, 9). Generally, it is believed that ASIA due to SIIS occurs when the implants are ruptured (10, 11). Silicone breast implants, however, may also “bleed” and silicone gel may subsequently stimulate the immune system as well (12, 13). At present, gel bleed cannot be ruled out in any silicone gel filled breast implant, no matter how the implant is fabricated. In conclusion, three sisters developed complaints such as fatigue, arthralgias and myalgias after the implantation of silicone breast prostheses that improved upon removal of the silicone implants. The development of ASIA due to SIIS in three siblings supports the hypothesis that genetic characteristics may determine whether this disorder will develop. Which genetic factor(s) is, however, at present unclear.

### References

1. COHEN TERVAERT JW, KAPPEL RM: Silicone implant incompatibility syndrome (SIIS): a frequent cause of ASIA (Shoenfeld's syndrome). *Immunol Res* 2013; 56: 293-8.
2. HAJDU SD, AGMON-LEVIN N, SHOENFELD Y: Silicone and autoimmunity. *Eur J Clin Invest* 2011; 41: 203-11.
3. KAPPEL RM, PRUIJN G: The Monobloc Hydrogel breast implant, experiences and

ideas. *Eur J Plast Surg* 2012; 35: 229-33.

4. MELMED EP: A review of explantation in 240 symptomatic women: a description of explantation and capsulectomy with reconstruction using a periareolar technique. *Plast Reconstr Surg* 1998; 101: 1364-73.
5. CSAKO G, COSTELLO R, SHAMIM EA *et al.*: Serum proteins and paraproteins in women with silicone implants and connective tissue disease: a case-control study. *Arthritis Res Ther* 2007; 9: R95.
6. BAR-MEIR E, TEUBER SS, LIN HC *et al.*: Multiple autoantibodies in patients with silicone breast implants. *J Autoimmun* 1995; 8: 267-77.
7. HU X, DALY M: What have we learned from six years of GWAS in autoimmune diseases, and what is next? *Curr Opin Immunol* 2012; 24: 571-5.
8. SHOENFELD Y, AGMON-LEVIN N: 'ASIA'-Autoimmune/inflammatory syndrome induced by adjuvants. *J Autoimmun* 2011; 36: 4-8.
9. MERONI PL: Autoimmune or auto-inflammatory syndrome induced by adjuvants (ASIA): Old truths and a new syndrome? *J Autoimmun* 2011; 36: 1-3.
10. BROWN SL, PENNELLO G, BERG WA, SOO MS, MIDDLETON MS: Silicone gel breast implant rupture, extracapsular silicone, and health status in a population of women. *J Rheumatol* 2001; 28: 996-1003.
11. VERMEULEN RC, SCHOLTE HR: Rupture of silicone gel breast implants and symptoms of pain and fatigue. *J Rheumatol* 2003; 30: 2263-7.
12. BARKER DE, RETSKY MI, SCHULZ S: “Bleeding” of silicone from bag-gel breast implants, and its clinical relation to fibrous capsule reaction. *Plast Reconstr Surg* 1978; 61: 836-41.
13. BEEKMAN WH, FEITZ R, VAN DIEST PJ, HAGE JJ: Migration of silicone through the fibrous capsules of mammary prostheses. *Ann Plast Surg* 1997; 38: 441-5.
14. ROUHL RP, DAMOISEAUX JG, LODDER J *et al.*: Vascular inflammation in cerebral small vessel disease. *Neurobiol Aging* 2012; 33: 1800-6.
15. THEWISSEN MM, DAMOISEAUX JG, DUIJVESTIJN AM *et al.*: Abdominal fat mass is associated with adaptive immune activation: the CODAM Study. *Obesity* 2011; 19: 1690-8.